



## IMAGES IN INTENSIVE MEDICINE

### From the macro to the micro. Diagnosis at first glance

### Desde la macro a la micro. Diagnóstico a primera vista



B. Cantan<sup>a</sup>, I. Martin-Loeches<sup>a,b,c,\*</sup>

<sup>a</sup> Department of Intensive Care Medicine, St James Hospital, Dublin, Ireland

<sup>b</sup> Multidisciplinary Intensive Care Research Organization (MICRO), St. James's Hospital Dublin, Ireland

<sup>c</sup> Department of Clinical Medicine, Trinity College, Wellcome Trust-HRB Clinical Research Facility, St James Hospital, Dublin, Ireland

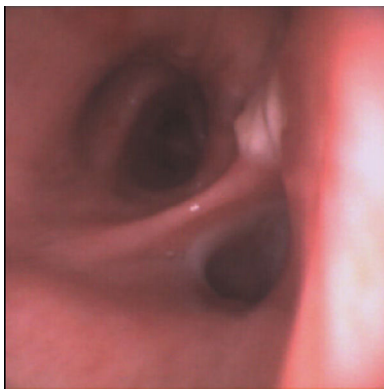


Figure 1

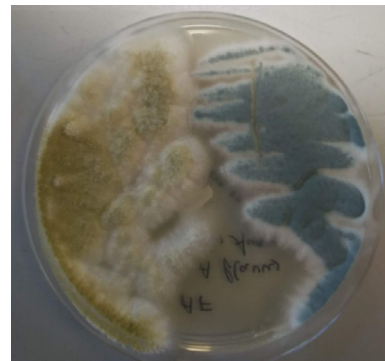

Figure 2

A 51 year old immunocompetent man was admitted to the intensive care unit with severe acute respiratory distress syndrome caused by influenza A infection. He initially responded well to treatment. His respiratory status subsequently deteriorated and he developed multi-organ failure which prompted suspicion of either a bacterial or fungal co-infection, a recognised complication of influenza infection. Bronchoscopy revealed multiple pseudomembranes in the trachea (Fig. 1) and right and left main bronchi. Samples from brushings and bronchoalveolar lavage were sent to the laboratory. Culture of these yielded both *Aspergillus flavus* and *Aspergillus fumigatus* (Fig. 2). Unfortunately despite appropriate treatment the patient progressed to refractory multi-organ failure and died.

### Funding

No funding to declare.

### Conflict of interest

No conflict of interest to declare.

\* Corresponding author.

E-mail address: [drmartinloeches@gmail.com](mailto:drmartinloeches@gmail.com) (I. Martin-Loeches).