



IMAGES IN INTENSIVE MEDICINE

Diagnosis of diaphragmatic paralysis by ultrasound after cardiac surgery**Diagnóstico de parálisis diafragmática tras cirugía cardíaca mediante ecografía pulmonar**A. Santos Peral^{a,*}, A. Gómez Carranza^a, R. Vicho Pereira^b^a Servicio de Medicina Intensiva, Hospital General Universitario de Ciudad Real, Ciudad Real, Spain^b Servicio de Medicina Intensiva, Clínica Rotger Quirónsalud - Hospital Mallorca, Palma de Mallorca, Spain

Available online 8 September 2022

This is the case of a 55-year-old patient admitted to the ICU after cardiac surgery to repair an ostium secundum-type interatrial communication and anomalous pulmonary venous drainage. After uneventful extubation is performed, the patient remains with hypoxemia and no alterations on the thoracic x-ray. The pulmonary ultrasound performed confirms the presence of a reduced right diaphragmatic movement compared to the left one (Video 1). Diaphragmatic excursion is measured with presence of a 16 mm reduced right excursion compared to a 60 mm left excursion (Fig. 1). These findings are consistent with right diaphragmatic paralysis associated with a probable lesion of the ipsilateral phrenic nerve during surgery. Conservative therapy with incentive spirometers is used. The patient progressed favorably until hospital discharge with persistent diaphragmatic dysfunction on the ultrasound.

* Corresponding author.

E-mail address: alfonso.stp@gmail.com (A. Santos Peral).

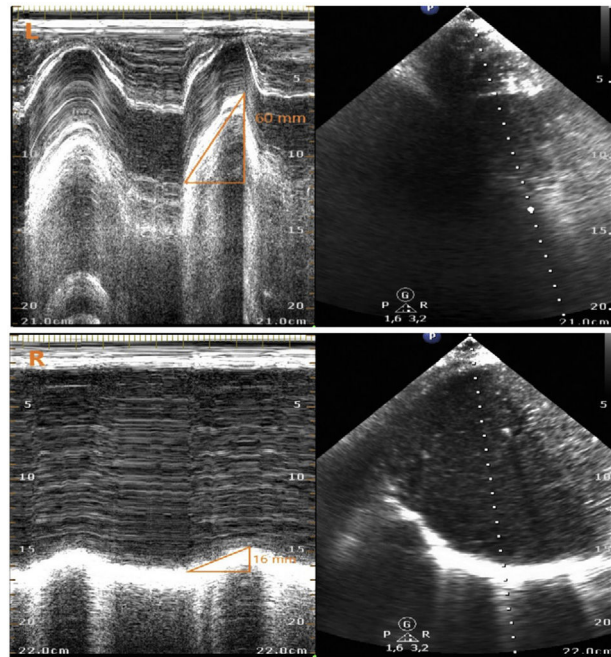


Figure 1

Appendix A. Supplementary data

Supplementary material related to this article can be found, in the online version, at doi:<https://doi.org/10.1016/j.medicine.2022.07.017>.