



IMAGES IN INTENSIVE MEDICINE

Neck pulsatility in a breathless patient

Pulso cervical en un paciente con disnea

J. Corona-Lapuerta^a, A. Roldan-Reina^b, L. Martin-Villen^{c,*}

^a Servicio de Medicina Intensiva, Hospital Universitario Infanta Elena, Valdemoro, Madrid, Spain

^b Critical Care and Anaesthesia, Royal Brompton and Harefield NHS Foundation Trust, London, UK

^c UGC Medicina Intensiva, Hospital Universitario Virgen del Rocío, Seville, Spain

Available online 19 October 2022

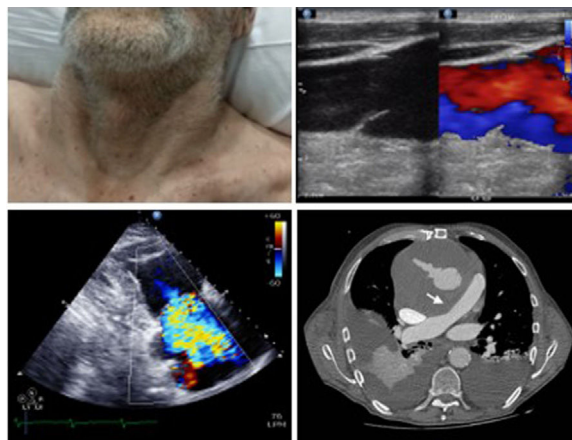


Figure 1

A 74-years-old man with a history of ascendant aortic dissection repaired 5 years ago and two mayor episodes of intrathoracic infection needing long-term antibiotic treatment, came to the ER for a presternal tumor. CT scan detected a preaortic mass suggestive of an aortic pseudoaneurysm. Surgery was planned but cancelled for mild respiratory infection, acute renal and hepatic failure, needing ICU admittance. In the ICU, the patient at physical exploration neck engorgement and pulsatility stood up (video 1). Vascular and cardiac bedside ultrasound showed a reversed systolic flow in the jugular veins (video 2) and a severe tricuspid regurgitation (video 3) secondary to pulmonary hypertension due to extrinsic compression of the pseudoaneurysm over the pulmonary artery (white arrow in Fig. 1). The patient rejected aggressive treatment and passed away 2 days later.

Appendix A. Supplementary data

Supplementary data associated with this article can be found, in the online version, at [doi:10.1016/j.medicina.2021.12.016](https://doi.org/10.1016/j.medicina.2021.12.016).

* Corresponding author.

E-mail address: luis.martin.villen.sspa@juntadeandalucia.es (L. Martin-Villen).