



IMAGES IN INTENSIVE MEDICINE

Hydrocephalus treatment monitoring on transcranial and abdominal ultrasound



Monitoreo del tratamiento de la hidrocefalia mediante ecografía transcraneal y abdominal

Pablo Blanco^{a,*}, Liliana Figueroa^a, Gustavo Ottaviano^b

^a High-dependency Unit, Hospital "Dr. Emilio Ferreyra", Necochea, Argentina

^b Service of Neurosurgery, Hospital "Dr. Emilio Ferreyra", Necochea, Argentina

Available online 13 February 2024

An 18-year-old male with a history of severe traumatic brain injury developed severe hydrocephalus (Fig. 1, asterisks) after bilateral decompressive craniectomy, as shown by transcranial ultrasound (TCU, Fig. 1A) and cranial computed tomography (CT, Fig. 1B). Subsequently, the patient underwent a one-stage bilateral cranioplasty and ventriculoperitoneal (VP) shunt placement. Postoperatively, a progressive reduction in lateral ventricle size was observed

on serial TCU (Fig. 1C) and CT as well (Fig. 1D). Notably, on abdominal ultrasound, the VP shunt catheter tip (Fig. 1E, arrow) was observed within the free peritoneal fluid (Fig. 1E, X-sign), indicating cerebrospinal fluid drainage. Ongoing monitoring of hydrocephalus and VP shunt function is an emerging application of point-of-care ultrasound that may aid in the early detection of system malfunction and expediting therapeutic interventions.

* Corresponding author.

E-mail address: ohтусabes@gmail.com (P. Blanco).

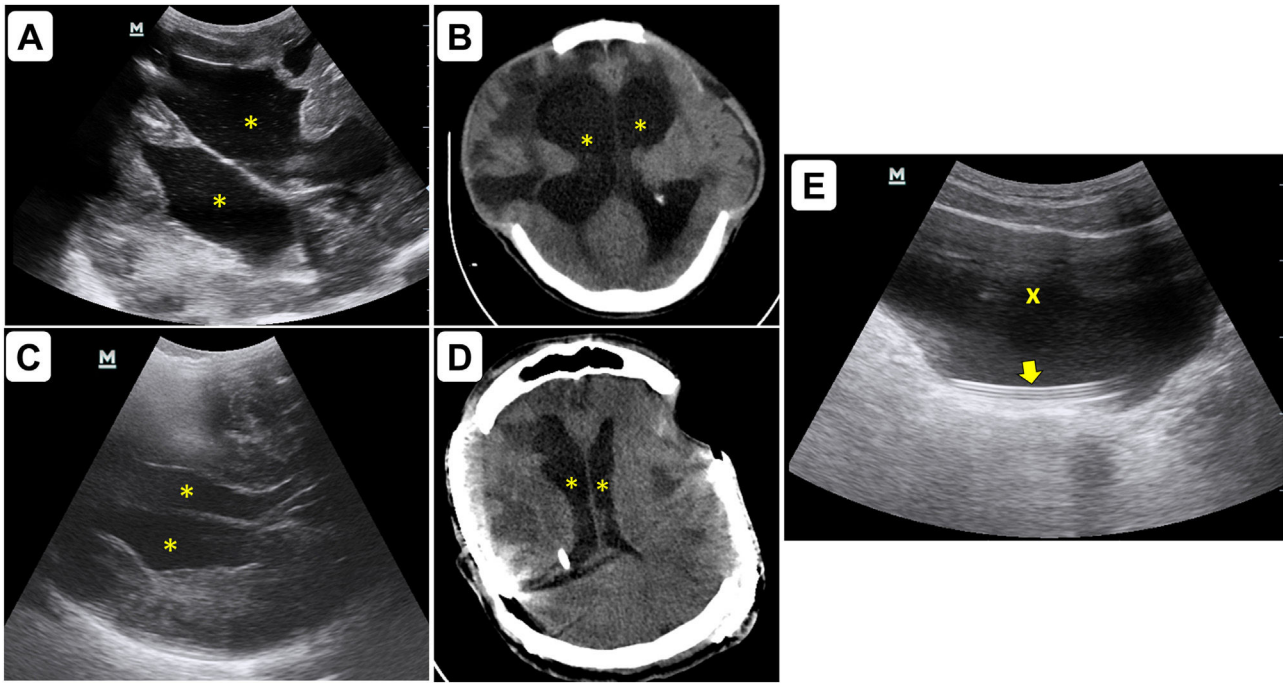


Figure 1

Funding

This work has not been supported by any grants.

Conflicts of interest

Authors have no conflicts of interest to disclose.

Authors' contributions

Pablo Blanco (PB) observed the case, performed the ultrasound examinations, contributed significantly to the drafting

and editing of the manuscript and created/edited the Figure. PB read and approved the final manuscript.

Liliana Figueroa (LF) observed the case and contributed significantly to the drafting and editing of the manuscript. LF read and approved the final manuscript.

Gustavo Ottaviano (GO) observed the case and contributed significantly to the drafting and editing of the manuscript. GO read and approved the final manuscript.