



IMAGES IN INTENSIVE MEDICINE

Cardiogenic shock due to a large apical pseudoaneurysm of the left ventricle: A rare complication

Shock cardiogénico por gran pseudoaneurisma apical del ventrículo izquierdo: una complicación infrecuente

Jaime Andrés Romero León*, Elena Morente García, Eva Peregrina Caño

Medicina Intensiva, Hospital Universitario Virgen de la Victoria, Málaga, Spain

Available online 7 June 2025



This is the case of a 61-year-old woman who had a myocardial infarction one month prior and subsequently developed post-infarction mechanical complications. The echocardiogram revealed the presence of a large apical pseudoaneurysm (Figs. 1 and 3: blue arrow) (Appendix A Video), with a 2.93 cm neck (Figs. 1 and 2: yellow arrow) and free flow of echocontrast through it (Fig. 2: red arrow). The lumen was partially thrombosed (Figs. 1 and 3: white arrow). She also exhibited severe left ventricular dilatation and very

severe global systolic dysfunction (Fig. 1) (LVEF 11%; LVOT VTI 7 cm). Forty-eight hours after admission, the patient developed SCAI C-D cardiogenic shock, requiring mechanical support with V-A ECMO and an intra-aortic balloon pump, which led to a significant improvement in organ perfusion. After coordination with the referral hospital, she underwent a code 0 heart transplant, with a favorable recovery. This case highlights the importance of echocardiographic diagnosis and mechanical support management in critical situations of cardiogenic shock.

DOI of original article: <https://doi.org/10.1016/j.medin.2025.502212>

* Corresponding author.

E-mail address: jaimeandrs@hotmail.com (J.A. Romero León).

<https://doi.org/10.1016/j.medicine.2025.502212>

2173-5727/© 2025 Elsevier España, S.L.U. and SEMICYUC. All rights are reserved, including those for text and data mining, AI training, and similar technologies.

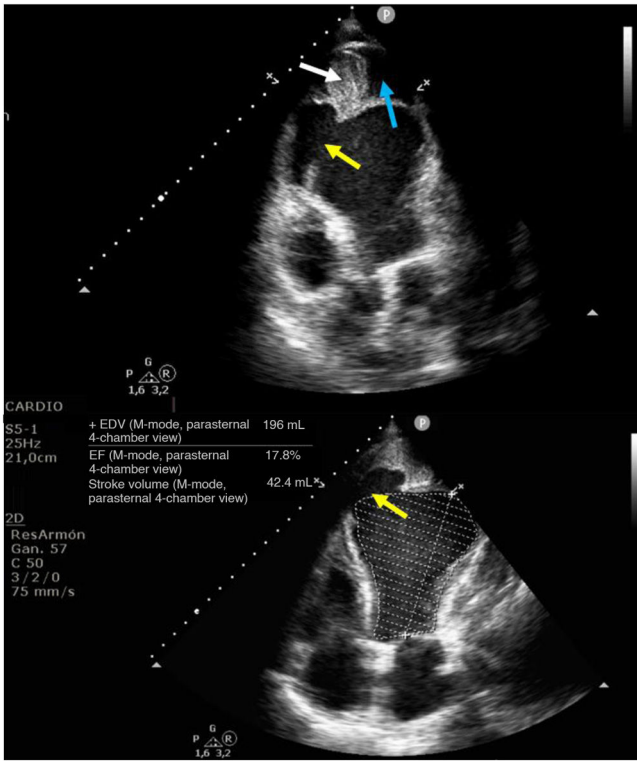


Figure 1

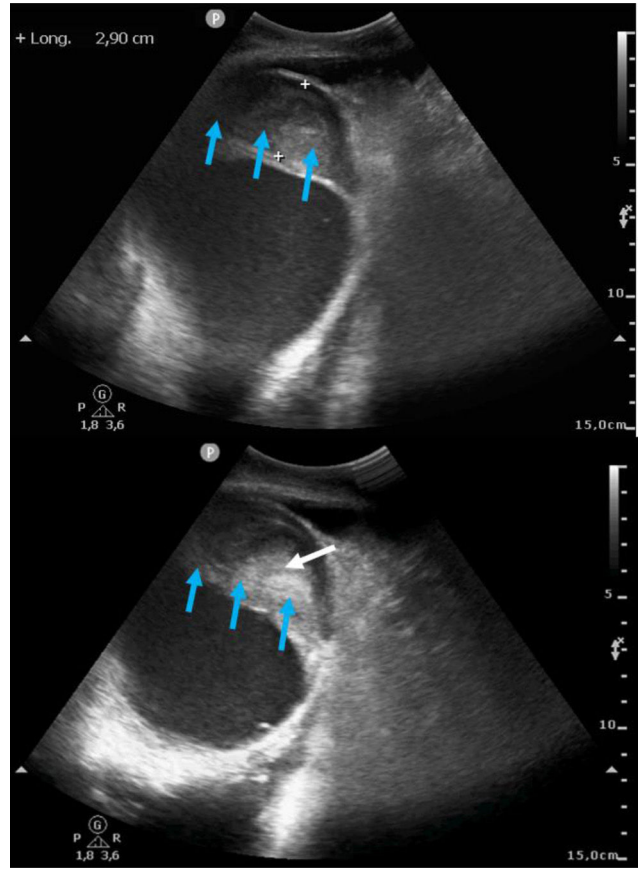


Figure 3

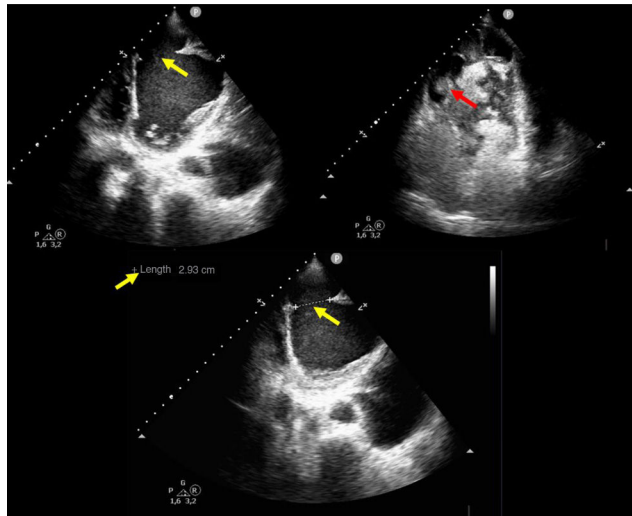


Figure 2

Funding

None declared.

Appendix A. Supplementary data

Supplementary material related to this article can be found, in the online version, at doi:<https://doi.org/10.1016/j.medic.2025.502212>.

Declaration of competing interest

None declared.