



## IMAGES IN INTENSIVE MEDICINE

### Inverted Tako-Tsubo cardiomyopathy as the first cardiac manifestation in patient with Steinert’s disease



### Tako-Tsubo invertido como primer evento cardiológico en un paciente con distrofia miotónica de Steinert

M. Negreira Caamaño <sup>a,\*</sup>, M.T. López Lluva <sup>a,b</sup>, J. Abellán Huerta <sup>a,b</sup>

<sup>a</sup> Servicio de Cardiología, Hospital General Universitario de Ciudad Real, Ciudad Real, Spain

<sup>b</sup> Unidad de Hemodinámica, Servicio de Cardiología, Hospital General Universitario de Ciudad Real, Ciudad Real, Spain

Available online 7 September 2022

This is the case of a 46-year-old man with Steinert’s disease brought to our center with syncope preceded by thoracic pain. The baseline EKG revealed the presence of sinus tachy-

cardia, first degree AV block, and left bundle branch block (Fig. 1A). During the cardiac examination, the patient developed an episode of syncope. Also, ventricular fibrillation was

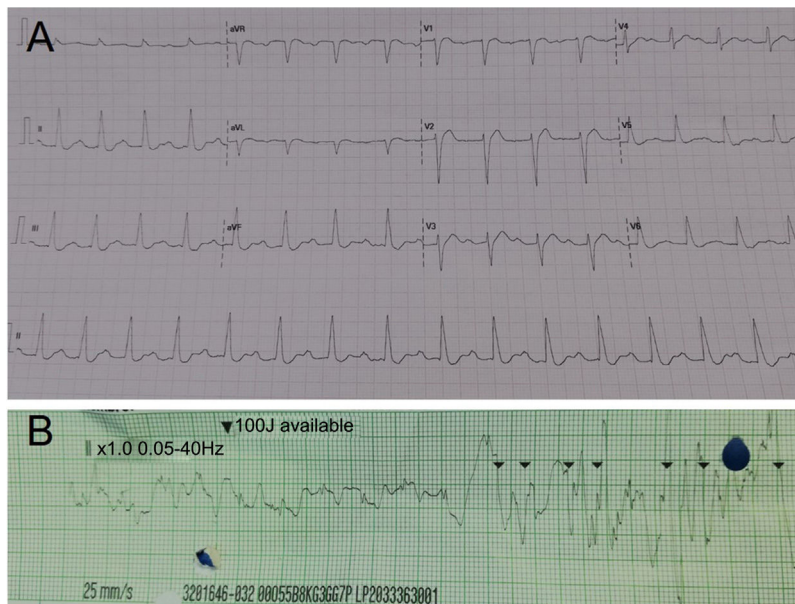


Figure 1

DOI of original article: <https://doi.org/10.1016/j.medin.2020.05.016>

\* Corresponding author.

E-mail address: [martin.negcam@gmail.com](mailto:martin.negcam@gmail.com) (M. Negreira Caamaño).

<https://doi.org/10.1016/j.medicine.2022.07.008>

2173-5727/© 2020 Elsevier España, S.L.U. and SEMICYUC. All rights reserved.

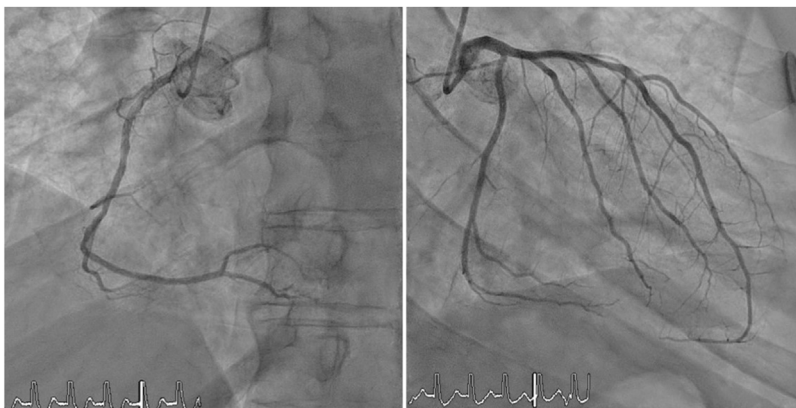


Figure 2

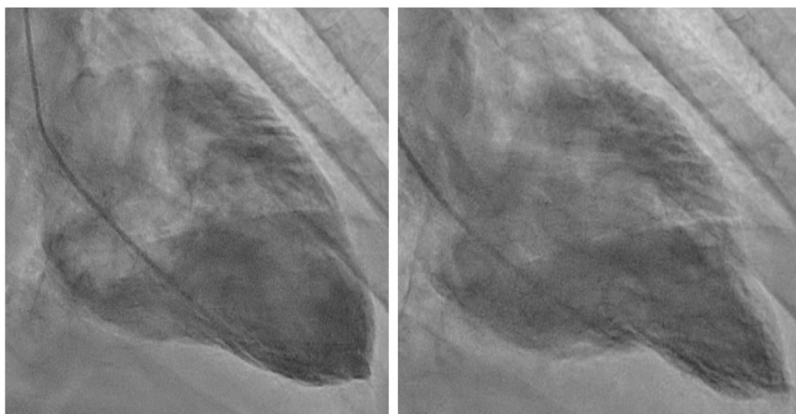


Figure 3

confirmed (Fig. 1B) that was solved after the administration of a 200J discharge. An emergency coronary angiography revealed the presence of normal coronary arteries (Fig. 2, videos 1 and 2) being ventriculography compatible with inverted Tako-Tsubo cardiomyopathy (Fig. 3, video 3). The enzymatic mobilization of cardiac biomarkers (hs-tnt) was discrete. One month after hospital discharge, the patient was assessed at the doctor's office and the transthoracic echocardiogram performed looked normal.

## Funding

None whatsoever.

## Appendix A. Supplementary data

Supplementary material related to this article can be found, in the online version, at doi:<https://doi.org/10.1016/j.medine.2022.07.008>.